

Retinal detachment with chronic intraocular foreign body

Category(ies): Retina, Vitreous

Contributor: [David Phillips, MD](#)

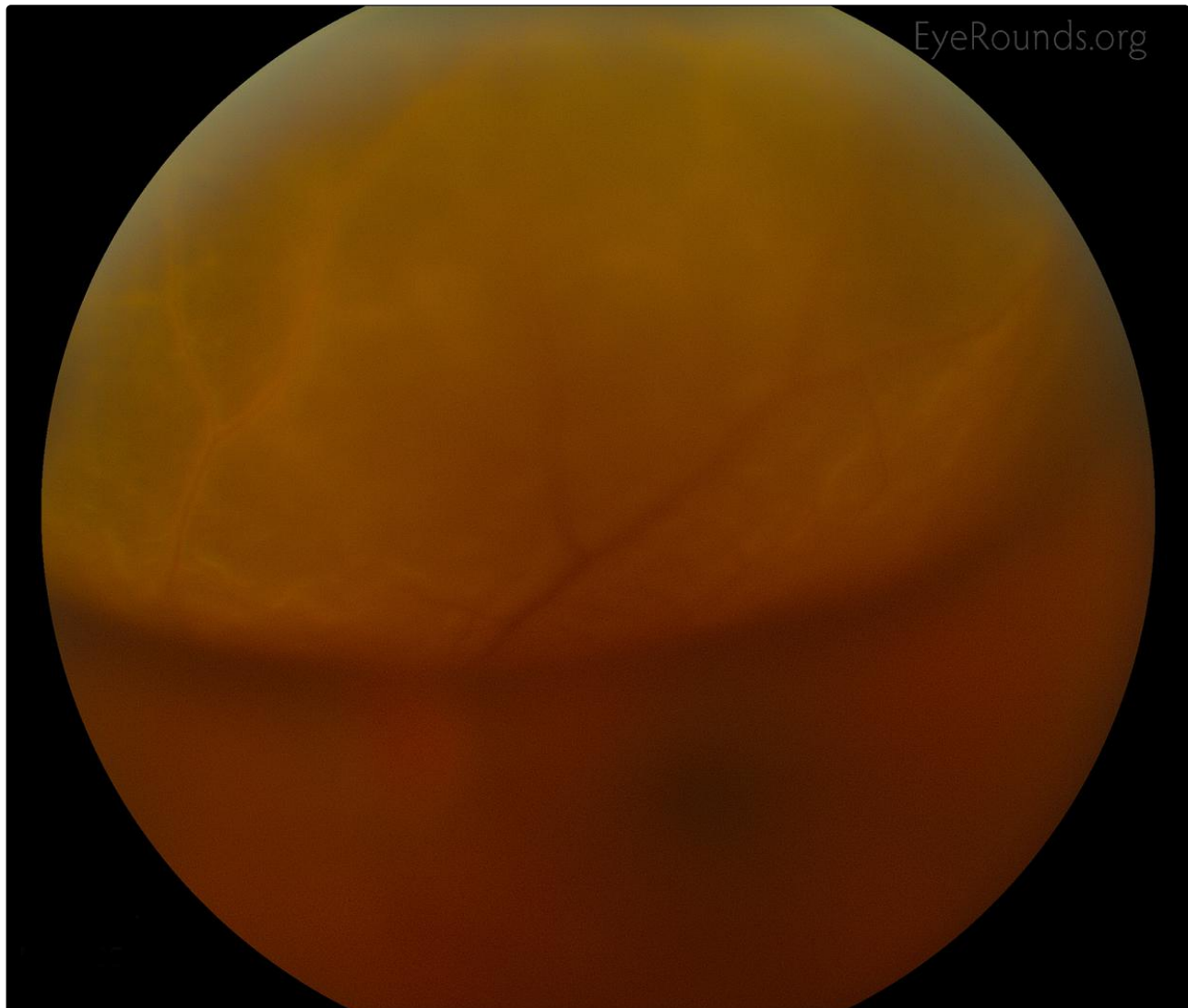
Photographer: Toni Venckus, CRA



This patient presented with acute photopsias and a retinal detachment was identified superiorly but incidentally a large metallic intraocular foreign body (IOFB) was noted on dilated exam. There was a history of remote ocular trauma to this eye while grinding metal 3 years prior.

There was no evidence of heterochromia but there was mild pigment dusting on the lens that was rust colored and consistent with siderosis. The IOFB is not visible in the fundus photograph, but is seen as a hyperechoic mass opposite the retinal detachment on the B-scan ultrasound.

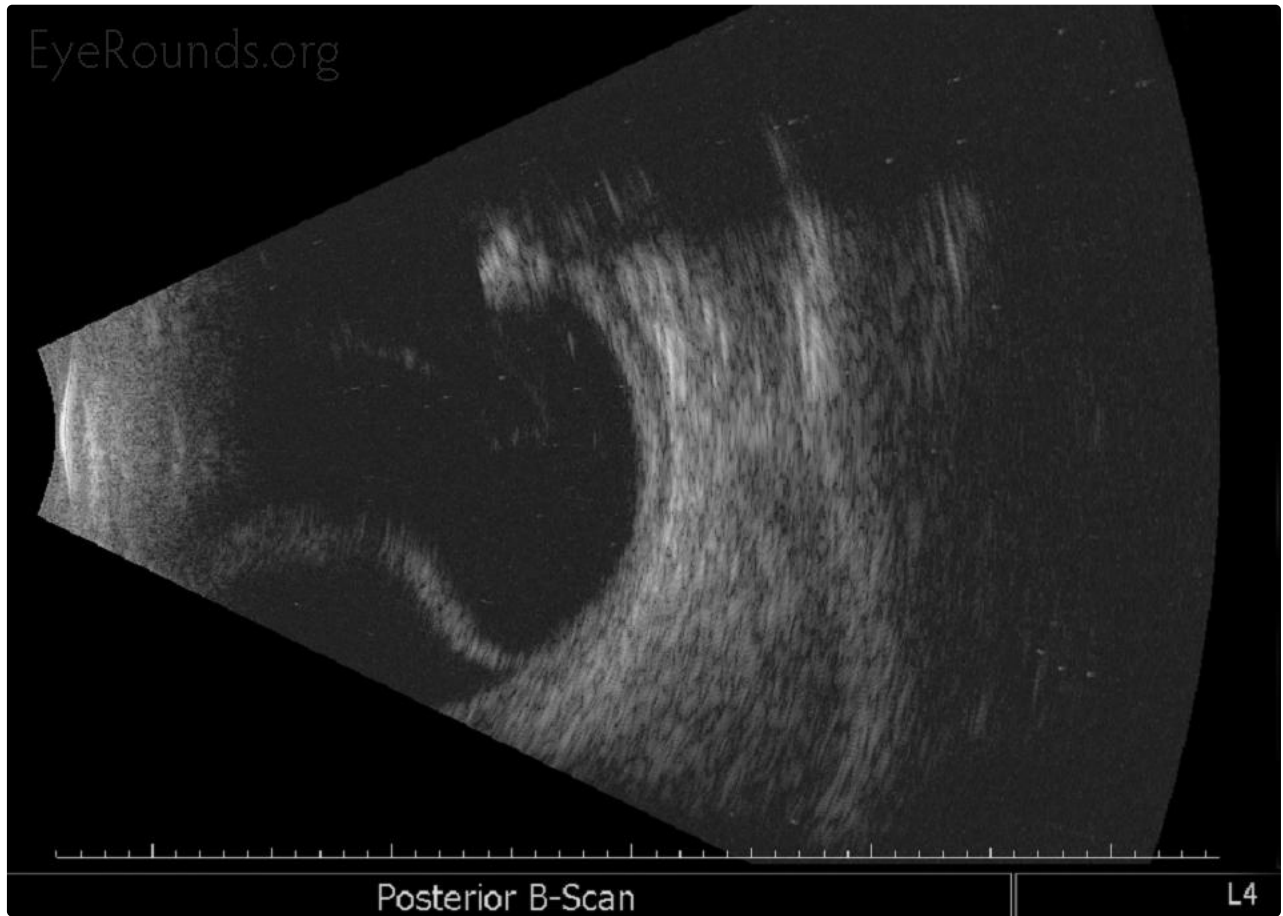The IOFB was removed with a rare earth magnet via pars plana approach. The retina was re-attached with perfluoro-n-octane (PFO) liquid, endolaser, air-fluid exchange, and 18% perfluoropropane (C3F8) gas. The only causative break found in the retina was at the site of the IOFB.



Enlarge

Download

EyeRounds.org



Posterior B-Scan

L4

Enlarge

Download

Image Permissions:



Ophthalmic Atlas Images by [EyeRounds.org](https://www.eyerounds.org), [The University of Iowa](https://www.theuniversityofiowa.edu) are licensed under a [Creative Commons Attribution-NonCommercial-NoDerivs 3.0 Unported License](https://creativecommons.org/licenses/by-nc-nd/3.0/).

Address

University of Iowa
Roy J. and Lucille A. Carver College
of Medicine
Department of Ophthalmology and
Visual Sciences
200 Hawkins Drive
Iowa City, IA 52242

Legal

Copyright © 2019 The University of
Iowa. All Rights Reserved
Report an issue with this page
Web Privacy Policy |
Nondiscrimination Statement

Related Links

Cataract Surgery for Greenhorns
EyeTransillumination
Gonioscopy.org
Iowa Glaucoma Curriculum
Iowa Wet Lab
Patient Information
Stone Rounds

EyeRounds Social Media

Follow



Receive notification of new cases,
sign up here
Contact Us

